

EP CASE REPORT

A shocking experience: inappropriate subcutaneous implantable cardioverter-defibrillator shock at a public swimming pool

Fabian Patrick Fastenrath^{1*}, Jürgen Kuschyk^{1,2†}, Martin Borggrefe^{1,2}, Ibrahim Akin^{1,2}, and Boris Rudic^{1,2}

¹1st Medical Department, I. Med Clinic - Cardiology, Angiology, Pulmonology and Intensive Care, University Medical Center Mannheim GmbH, Medical Faculty Mannheim, University of Heidelberg, Theodor-Kutzer-Ufer 1-3, 68167 Mannheim, Germany; and ²DZHK (German Centre for Cardiovascular Research), Partner Site Mannheim, Mannheim, Germany

* Corresponding author. Tel: +49 621 383 4231; fax: +49 621 383 3061. E-mail address: Fastenrath@stud.uni-heidelberg.de

† This author contributed equally to the study.

Introduction

The subcutaneous implantable cardioverter-defibrillator (S-ICD) has been increasingly used in the primary and secondary prevention of sudden arrhythmogenic death. Its proven efficacy is challenged by the occurrence of inappropriate shocks in 8, 3–13, 1% of patients.¹ Due to its distinctive electrocardiography-sensing method, inappropriate therapy is often a result of signal-oversensing. Not much is known about possible interferences with external sources of electromagnetic activity, however, anecdotal cases have been published previously.²

Case report

A 67-year-old male patient experienced an inappropriate shock 44 months after S-ICD implantation, while guarding his grandchildren in a public swimming pool, next to a waterslide. In October 2014, the patient was implanted with an S-ICD (Boston Scientific, 1010 SQ-RX) for primary prevention due to ischaemic cardiomyopathy with reduced left ventricular ejection fraction. His follow-up was uneventful to this point. Device interrogation revealed high-frequency signals, misinterpreted as ventricular fibrillation, followed by inappropriate therapy delivery with 80 J (Figure 1A). The patient had no symptoms of dizziness, palpitations, chest pain, or syncope prior to the incident. Further interrogation showed proper device functionality, as well as regular sensing on all vectors.

As the patient had remained conscious throughout the incident, we were able to return to the scene. We interrogated the device at different positions using an S-ICD programming device, until we were able to reconstruct the situation. Figure 1B shows the reproduced

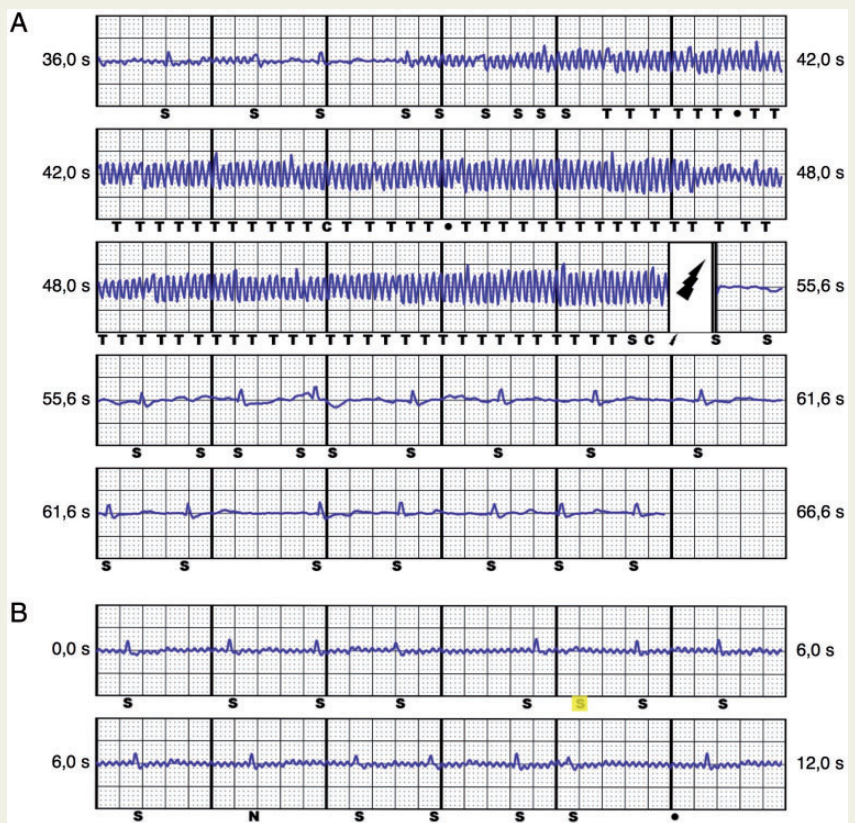


Figure 1 (A) Interrogation of the S-ICD reveals high-frequency electromagnetic signals, which were detected and misclassified as ventricular fibrillation by the S-ICD. Our patient was holding to the metallic handrail, and let go, by the moment of the inappropriate shock. This led to a disappearance of the signals and return to baseline ECG detection. (B) Screenshot of the reproduced episode, showing electromagnetic interference/noise leading to inappropriate sensing (marked in yellow). The patient was standing barefoot on wet tiles, holding on to a metallic handrail, in close proximity of the water pump supplying the waterslide. ECG, electrocardiography; S-ICD, subcutaneous implantable cardioverter-defibrillator.

electromagnetic interference of approximately 30 Hz, when the patient held on to a metallic handrail next to the waterslide, which was supplied by a water pump, installed adjacent to the handrail. Therapy delivery was withheld at all times during the provocation manoeuvre.

Discussion

Electromagnetic interference (EMI) is not new to ICD and pacemaker therapy. Similar cases of inappropriate ICD therapy at swimming pools have been reported with transvenous ICDs previously.³ The S-ICD however, uses a different sensing method with higher chance of far-field interference. Its susceptibility to EMI is yet to be determined.

The S-ICD is especially used in young patients that are unlikely to benefit from antitachycardia pacing and have no pacing requirement. However, this young patient population remains more active in everyday life. This case report displays a challenge in S-ICD therapy guidance, as it draws out the thin line between impairing further quality of life and increased risk of inappropriate therapy.

It remains questionable, how often and in which situations EMI occurs in S-ICD patients on a daily basis. Furthermore, patients should be advised not only to keep distance to strong electromagnetic fields, but also to bare in mind, that possible current leakage on metallic surfaces in the vicinity of electric generators may occur.

Conflict of interest: none declared.

References

1. Olde Nordkamp LR, Brouwer TF, Barr C, Theuns DA, Boersma LV, Johansen JB *et al.* Inappropriate shocks in the subcutaneous ICD: incidence, predictors and management. *Int J Cardiol* 2015;**195**:126–33.
2. Frommeyer G, Reinke F, Eckardt L, Wasmer K. Inappropriate shock in a subcutaneous ICD due to interference with a street lantern. *Int J Cardiol* 2015;**198**:6–8.
3. Makaryus JN, Angert-Gilman J, Yacoub M, Patel A, Goldner B. Inappropriate implantable cardioverter-defibrillator shocks attributed to alternating-current leak in a swimming pool. *Tex Heart Inst J* 2014;**41**:61–3.